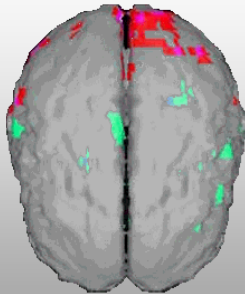
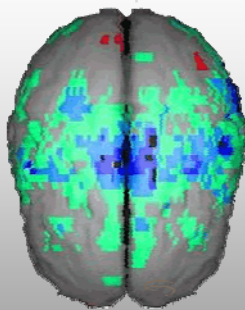


## Alzheimer's Disease



Normal



Alzheimer's Disease

### Case Study

*Clinical History:* The patient is a 73-year-old, retired male dentist who has exhibited a progression of cognitive problems during the past 6 years. The patient is otherwise very healthy and has an active lifestyle.

#### Symptoms:

- Fatigue
- Confusion
- Memory problems
- Decreased judgment
- Depressive symptoms
- Difficulty concentrating
- Problems doing familiar tasks
- Disorientation to time & place

*Brain SPECT Findings:* Bi-parietal and bi-temporal hypoperfusion as well as decreased posterior cingulate perfusion are consistent with a neurodegenerative process such as Alzheimer's disease. Degenerative changes throughout the frontal lobes, widening of the third ventricle, and expansion of the lateral ventricles are probably due to diffuse degenerative cerebral changes.

CereScan Corp.  
300 South Jackson Street  
Denver, CO 80209

866-722-4806  
CereScanImaging.com