CereScan
High Definition Brain Imaging

ADHD/ADD

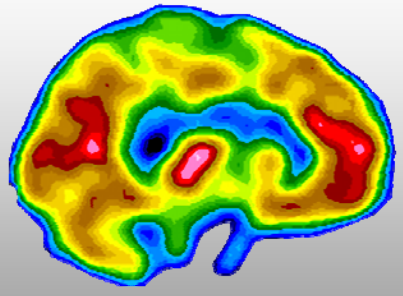

Baseline

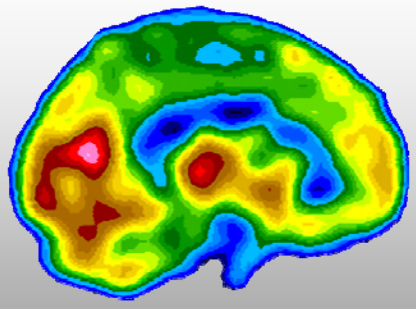

Test

Case Study

Clinical History: **This patient is a 23-year-old male. His symptoms include difficulty sustaining attention, listening, organizing, following instructions and paying attention to details, avoidance of tasks that require sustained mental effort, distractibility, forgetfulness, restlessness, fidgetiness and excessive talking.**

Brain SPECT Findings **: The patient's brain SPECT report include decreased activity in the anterior cingulate gyri, orbital frontal area, prefrontal poles and anterior temporal lobes with test consistent with an attention deficit hyperactivity disorder-like process.**

CereScan Corp.
300 South Jackson Street
Denver, CO 80209

866-722-4806
CereScanImaging.com